

## HARLEQUIN BABY SYNDROME- A RARE AUTOSOMAL RECESSIVE SKIN DISORDER

Gummalla Pitchaiah\*

Department of Pharmacology, Hindu College of Pharmacy, Amaravathi Road, Guntur - 522 002, Andhra Pradesh, India.

### ABSTRACT

The term harlequin baby is used for newborns in whom all the body surface covered with a thick skin sheets resembling an armor. In addition, there are deep fissures on the skin. It is an autosomal recessive disorder with the majority of affected individuals being homozygous for mutation in the ABCA12 gene. Clinically, the harlequin babies may encounter dehydration, electrolyte imbalance, temperature malfunction and increasing sepsis risk because of severe skin damage. Therefore, affected neonates usually do not survive beyond first few days of life. High quality management of new born babies may improve survival. Introduction of oral retinoids and frequent application of emollients to improve barrier function is critical.

**Keywords:** Harlequin Baby, Skin, Autosomal recessive, ABCA12 gene.

### INTRODUCTION

Ichthyosis is a heterogeneous family of skin disorders, harlequin ichthyosis being the most severe form of congenital ichthyosis presenting at birth. This condition also known as harlequin baby syndrome, ichthyosis congenita gravior, harlequin fetus type or keratosis diffusa fetalis. The first report was made by Oliver Hart, of Charleston, South Carolina, who described some features of this disorder in 1750. India's first recorded case of a harlequin ichthyosis baby was reported in Nagpur in June 2016. The name 'Harlequin' is derived from the striking resemblance of the skin of these babies to the costume of the comic servant character 'archetypal Harlequin'.<sup>1, 2</sup> Infants with this condition are born with very hard, thick skin covering most of their bodies. The skin forms large, diamond-shaped plates that are separated by deep cracks (fissures). These skin abnormalities affect the shape of the eyelids, nose, mouth, and ears, and limit movement of the arms and legs. Restricted movement of the

chest can lead to breathing difficulties and respiratory failure.<sup>3, 4</sup>

The skin normally forms a protective barrier between the body and its surrounding environment. The skin abnormalities associated with harlequin ichthyosis disrupt this barrier, making it more difficult for affected infants to control water loss, regulate their body temperature, and fight infections. Infants with harlequin ichthyosis often experience an excessive loss of fluids (dehydration) and develop life-threatening infections in the first few weeks of life. The disorder has an ominous prognosis and affected babies usually die in first days to weeks of life.<sup>5</sup> However, with intensive medical support and improved treatment, people with this disorder now have a better chance of living into childhood and adolescence.

### Epidemiology

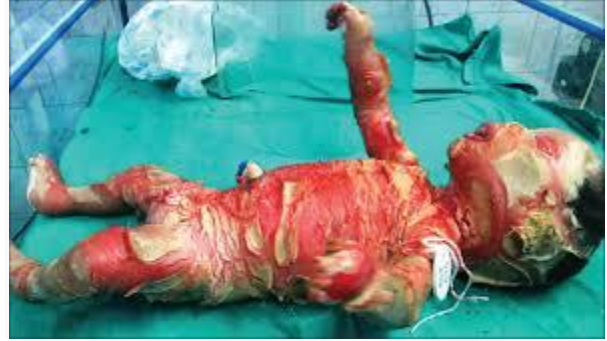**Frequency:** Approximately 200 cases of harlequin ichthyosis have been reported. The incidence is calculated to be around 1 case in 300,000 births.<sup>6</sup>

**Race:** No racial predilection is known for harlequin ichthyosis. A higher incidence may be encountered in cultures where parental consanguinity is common.<sup>7</sup>

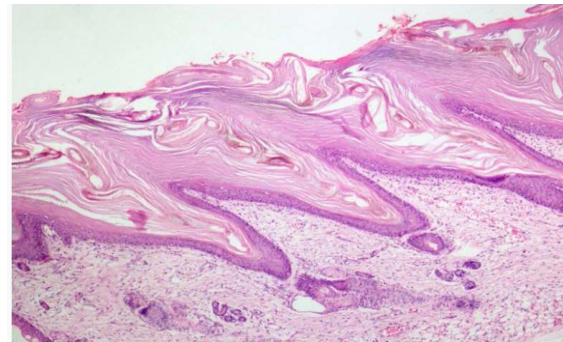
**Sex:** Sex distribution appears to be equal.

### Clinical Symptoms<sup>8,9</sup>

- **Skin:** Severely thickened skin with large, shiny plates of hyperkeratotic scale is present at birth. Deep, erythematous fissures separate the scales.
- **Eyes:** Severe ectropion is present. The free edges of the upper and lower eyelids are everted, leaving the conjunctivae at risk for desiccation and trauma.
- **Ears:** The pinnae may be small and rudimentary or absent.
- **Lips:** Severe traction on the lips causes eclabium and a fixed, open mouth. This may result in feeding difficulties.
- **Nose:** Nasal hypoplasia and eroded nasal alae may occur.
- **Extremities:** The limbs are encased in the thick, hyperkeratotic skin, resulting in flexion contractures of the arms, the legs, and the digits. Limb motility is poor to absent. Circumferential constriction of a limb can occur, leading to distal swelling or even gangrene. Hypoplasia of the fingers, toes, and fingernails is reported. Polydactyly is described.
- **Temperature dysregulation:** Thickened skin prevents normal sweat gland function and heat loss. The infants are heat intolerant and can become hyperthermic.
- **Respiratory status:** Restriction of chest-wall expansion can result in respiratory distress, hypoventilation, and respiratory failure.
- **Hydration status:** Dehydration from excess water loss can cause tachycardia and poor urine output.
- **Central nervous system:** Metabolic abnormalities can cause seizures. CNS depression can be a sign of sepsis or hypoxia. Hyperkeratosis may restrict spontaneous movements, making neurological assessment difficult.



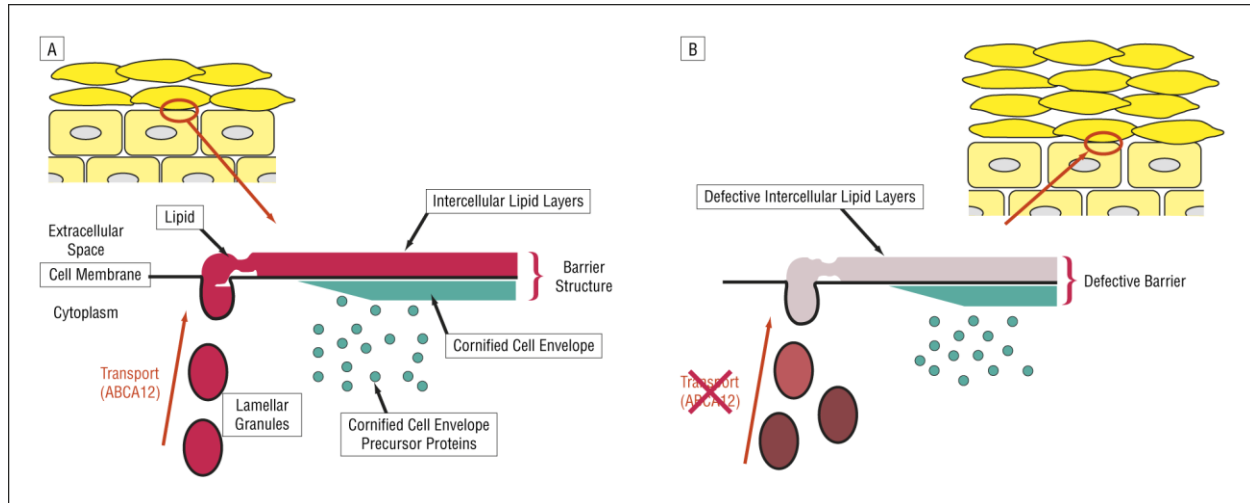
**Fig. 1: Harlequin Baby**



**Fig. 2: Extensive hyperkeratosis in stratum corneum layer of the harlequin patient's epidermis.**

### Genetic changes and inheritance pattern

Mutations in the ABCA12 gene cause harlequin ichthyosis. The ABCA12 gene provides instructions for making a protein that is essential for the normal development of skin cells. This protein plays a major role in the transport of fats (lipids) in the outermost layer of skin (the epidermis). Some mutations in the ABCA12 gene prevent the cell from making any ABCA12 protein. Other mutations lead to the production of an abnormally small version of the protein that cannot transport lipids properly. A loss of functional ABCA12 protein disrupts the normal development of the epidermis, resulting in the hard, thick scales characteristic of harlequin ichthyosis.<sup>8, 10</sup> This condition is inherited in an autosomal recessive pattern, which means both copies of the gene in each cell have mutations. The parents of an individual with an autosomal recessive condition each carry one copy of the mutated gene, but they typically do not show signs and symptoms of the condition.<sup>11</sup>



**Fig. 3: Presence (A) and loss (B) of functional ABCA12 protein**

### Diagnosis

The development of harlequin ichthyosis phenotype is initiated by the onset of hair canal keratinization at 17 weeks of gestation and is expressed in the entire hair carrying skin from 20 weeks of gestation onwards.<sup>12</sup> Three dimensional (3D) ultrasonography may show certain features like rudimentary ears, flexion contractures, and floating particles in the amniotic fluid suggestive of harlequin ichthyosis. Even if there is no history of HI in family, features like large and gaping mouth, aplasia of the nose, abnormal limbs, and bulging eyes on 3D scans may help in diagnosis. Two-dimensional ultrasonography can also demonstrate features of harlequin ichthyosis but not until late in the second trimester, when enough keratin buildup is present to be sonographically detectable. Short feet may be an early marker for harlequin ichthyosis.<sup>13</sup> Cells from the peripheral blood smear or the skin can be obtained and complete sequential analysis of the coding region of the ABCA12 gene can be carried out to identify the specific mutations, which lead to the development of harlequin ichthyosis.<sup>14</sup> Electron microscopic examination of the fetal skin biopsy permits the possibility of prenatal diagnosis of this disorder.<sup>15</sup>

### Management

Management of Harlequin baby needs a multidisciplinary approach. Most die in the perinatal period due to feeding problem, infection, and respiratory failure. Recently some of the affected neonates are surviving beyond

neonatal period with proper treatment. Initial treatment of this condition includes high fluid intake to avoid dehydration from trans epidermal water loss and use of a humidified heated incubator. Creams or ointments are used to keep the skin soft and hydrated. Keratolytic agents will promote peeling and thinning of the stratum corneum.<sup>16</sup>

Lubrication of the cornea in cases with ectropion prevents corneal drying. The role of prophylactic antibiotic is questionable, however, it is a prudent practice, in particular in the developing world to cover the baby with broad spectrum antibiotics to which local microbiological flora are known to be sensitive. Nevertheless, infants given these therapies almost invariably succumb to their disease from sepsis, inability to feed, and inadequate ventilation.<sup>17</sup> Oral retinoids (1 mg/kg/day) therapy has changed the scenario. With its use quality of life being improved and survival well into childhood had been documented. Infants receiving retinoids must be monitored for toxic effects. All survivors have had severe ichthyosis as an outcome; some have intellectual impairment also. Genetic counseling for the families is mandatory.<sup>18</sup> Ideally, a team comprising pediatrician, dermatologist, geneticist, ophthalmologist, reconstructive surgeon, should make an individualized plan for management along with full involvement of the parents or the care givers.

### CONCLUSION

Since, there are 25 % chances of recurrence in future pregnancies, harlequin baby syndrome

should be regarded as a severe chronic disease. Timely diagnosis, improved neonatal care, early introduction of proper treatment and simple measures, including daily bathing and liberal emollients, the number of survivors with harlequin baby syndrome can be better.

## REFERENCES

1. Charu Sharma, Tapan KB, Abhishek Bhardwaj and Manju Mehrotra. Harlequin Ichthyosis: a rare congenital dermatological disorder. *Int J Reprod Contracept Obstet Gynecol.* 2015;4(6):2100-2102.
2. <http://www.newindianexpress.com/nation/In-dias-first-Harlequin-Baby-born-in-Nagpur> .
3. Belengeanu V, Stoicanescu D, Stoian M, Andreescu N and Budisan C. Ichthyosis congenita, harlequin fetus type: a case report. *Adv Med Sci.* 2009; 54:113-5.
4. Karl LM. Disorder of keratinization. In Robert M. Kliegman, Bonita F. Stanton, Joseph W. St Geme III, Nina F. Schor. *Nelson Textbook of Pediatrics.* 1st south asia ed. New Delhi: Reed Elsevier India Pvt. Ltd. 2015. p.3171.
5. Shwayder T and Akland T. Neonatal skin barrier: structure, function and disorders. *Dermatol Therapy.* 2005;18:87-103.
6. Ahmed H and O'Toole EA. Recent advances in the genetics and management of harlequin ichthyosis. *Pediatr Dermatol.* 2014;31(5): 539-46.
7. Rajpopat S, Moss C, Mellerio J, Vahlquist A, Gånemo A, Hellstrom-Pigg M et al. Harlequin ichthyosis: a review of clinical and molecular findings in 45 cases. *Arch Dermatol.* 2011;147(6): 681-6.
8. Kelsell DP, Norgett EE, Unsworth H, Teh MT, Cullup T, Mein CA, Dopping-Hepenstal PJ et al. Mutations in ABCA12 underlie the severe congenital skin disease harlequin ichthyosis. *Am J Hum Genet.* 2005;76(5):794-803.
9. Bonifas JM, Morley BJ, Oakey RE, Kan YW and Epstein EH. Cloning of a cDNA for steroid sulfatase: frequent occurrence of gene deletions in patients with recessive X chromosome-linked ichthyosis, *Proc Natl Acad Sci.* 1987;84:9248-51.
10. Mitsutake S, Suzuki C, Akiyama M Tsuji K, Yanagi T, Shimizu H et al. ABCA12 dysfunction causes a disorder in glucosylceramide accumulation during keratinocyte differentiation. *J Dermatol Sci.* 2010;60:128.
11. Akiyama M. The pathogenesis of severe congenital ichthyosis of the neonate. *J Dermatol Sci.* 1999;21:96-104.
12. Zapalowicz K, Wygledowska G, Roszkowski T and Bednarowska A. Harlequin ichthyosis-difficulties in prenatal diagnosis. *J Appl Genet.* 2006;47(2):195-7.
13. Watson WJ and Mabee LM. Prenatal diagnosis of severe congenital Ichthyosis (harlequin fetus) by ultrasonography. *J Ultrasound Med.* 1995;14(3):241- 3.
14. Alok Kumar Dubey, Ilisapeci Vereti Tuibeqa and Nina Baivou Pio. Harlequin ichthyosis: A rare dermatological disorder. *Int J Case Rep Images.* 2014; 5(8): 590-594.
15. Blanchet-Bardon C, Dumez Y, Labbe F, Lutzner MA, Puissant A, Henrion R et al. Prenatal diagnosis of Harlequin fetus. *Lancet.* 1983;1(8316): 32.
16. Milstone LM and Choate KA. Improving outcomes for harlequin ichthyosis. *J Am Acad Dermatol.* 2013; 69(5): 808-9.
17. Chua CN and Ainsworth J. Ocular management of harlequin syndrome. *Arch Ophthalmol.* 2001;119(3):454-5.
18. Koochek A, Choate KA and Milstone LM. Harlequin Ichthyosis: Neonatal Management and Identification of a New ABCA12 Mutation. *Pediatr Dermatol.* 2014;31(2): e63-4.