

INTERNATIONAL JOURNAL OF RESEARCH IN PHARMACY AND CHEMISTRY

Available online at www.ijrpc.com

Research Article

PHARMACOLOGICAL EVALUATION OF STEM OF *CALOTROPIS PROCERA* FOR
HEPATOPROTECTIVE ACTIVITY**Akhilesh Sharma*, Gajendra S Rathore, Mayank S Sharma, Veermaram Choudhary,
Brijesh Kumar and Anil Bhandari**Faculty of Pharmaceutical Sciences, Jodhpur National University, Narnadi, Boranada, Jodhpur,
Rajasthan, India.*Corresponding Author: robinak@rediffmail.com**ABSTRACT**

The Stem of *Calotropis procera* are used for liver disorders in the traditional system of medicine. The aim of the present study is to evaluate the hepatoprotective activity of stem of *Calotropis procera* against Carbon tetrachloride induced hepatotoxicity. Hepatotoxicity was induced in albino rats of either sex by subcutaneous injection of carbon tetrachloride. Ethanolic extract of stem of *Calotropis procera* (250 and 500 mg/kg/day were evaluated). Oral administration of *Calotropis procera* at 250 and 500 mg/kg resulted in a significant reduction in serum aspartate aminotransaminase (40.31 % and 28.67 %, respectively), alanine aminotransaminase (58.04 % and 23.19 %, respectively), acid phosphatase (42.42 % and 19.53 %, respectively), total bilirubin (17.5 % and 26.05 %, respectively) when compared with carbon tetrachloride damaged rats. Histology of the liver sections of the animals treated with the extracts also showed dose-dependent reduction of necrosis.

Keywords: *Calotropis procera*, hepatoprotective, SGOT, SGPT, Total bilirubin.**INTRODUCTION**

A large number of plants and formulations have been claimed to have hepatoprotective activity. In India more than 87 plants are used in 33 patented and proprietary polyherbal formulations. In spite of tremendous advances made, only a few significant and effective hepatoprotective agents, e.g., silymarin, are available in modern therapeutics.

Calotropis procera (Asclepiadaceae) is a desert plant known as Ushar or madar in greeko-arab medicine. This plant is widely distributed in tropical and subtropical Africa and Asia. The medicinal use of this plant was known to ancient Egyptians, the excavation at Helwan in Egypt showed that the plant was in use in Neolithic period in Egypt.

Root-rough, fissured longitudinally, corky and soft, externally yellowish-grey while internally white, central core cream coloured, bark easily

separated from xylem, odour, characteristic: taste, bitter and acrid. Phytochemical investigation of *Calotropis procera* revealed the presence of glycosides such as calotropin, calactin, calatoxin, calotropagenin. The leaves contain ascorbic acid, calatropagenin and root has benzolisolineolone. The plant has been regarded as antidiarrhoeal, antipyretic, anti-inflammatory, antimalarial, antioxidant, antimicrobial, antihelmintic, antitumor, antihyperglycemic and analgesic.

The hepatoprotective activity of hydro-ethanolic extract (70%) of *Calotropis procera* flowers was reported against paracetamol induced hepatitis in rats in preliminary studies. Keeping in view its above use, the present study was aimed to evaluate the hepatoprotective activity of stem extract of *Calotropis procera* against carbon tetrachloride-induced hepatotoxicity.

MATERIAL AND METHODS

Plant materials

The dry stem of *Calotropis procera* was collected from Jodhpur region authentication was obtained from Botanical Survey of India, Jodhpur. Voucher specimens of *Calotropis procera* were kept in the institute for further references.

Preparation of plant extracts

The coarse powder (10 g) of the dried stem of *Calotropis procera* was exhaustively extracted using 50 mL of 70% (v/v) of ethanol in a soxhlet extractor for a period of 36 h. The extract was evaporated to dryness on water bath.

Yield of *Calotropis procera* extract = 7.6% (w/w).

Experimental animals

Healthy Wistar-Albino rats of either sex, weighing 180–220 g were used in the study. The animals were maintained at standard housing conditions and fed standard pellet diet and water *ad libitum*. All procedures were performed according to the Institutional Animal Ethics Committee's approval.

Hepatoprotective studies

Hepatotoxicity was induced by the subcutaneous administration of carbon tetrachloride in olive oil (1:1), at a dose of 2 ml/kg body weight twice a week. Five rats were used per group in the study. Carbon tetrachloride 2ml/kg was administered twice a week in the 7-day study period to all of the groups of animals except group I, which served as control and received the normal saline 5ml/kg once daily. Group II served as Carbon tetrachloride control. Group III received *Calotropis procera* extract at 250 mg/kg/day dose, Group IV received *Calotropis procera* extract at 500 mg/kg/day dose and group V received Silymarin at 100 mg/kg/day dose.

Assessment of liver function

1. Biochemical estimations

Blood samples were collected by puncturing the retro-orbital plexus with the help of microcapillary tubes under light ether anaesthetic. Serum was separated by centrifugation at 1000 rpm for 10 minutes. The serum was used for the biochemical analysis, which includes aspartate aminotransaminase,

AST; alanine aminotransaminase, ALT; alkaline phosphatase, ALP; and total bilirubin.

2. Histopathological studies

The liver from one animal of each group which shows maximum response were taken and were preserved in 10% buffered neutral formalin saline, dehydrated in graded (50-100%) alcohol and embedded in paraffin. The paraffin sections were then stained with alum haematoxylin and eosin for observing the liver damage.

Statistical analysis

The mean values SEM were calculated for each parameter. For determining the significant inter group difference, each parameter analyzed separately and oneway analysis of variance (ANOVA) was used. The individual comparisons of group mean values were done using Dunnett's test using graph pad prism software with P value $P < 0.05$ considered significant.

RESULTS

The administration of carbon tetrachloride resulted in a marked increase in serum SGPT, SGOT, ACP, ALP, total bilirubin levels. The groups treated with *Calotropis procera* extract showed significant decrease in the level of serum marker enzymes as compared with CCl_4 treated group.

The results showed in the table 1 and 2 exhibits the significant hepatoprotective effects of the *Calotropis procera* extract. The level of AST, ALT, and ALP were analyzed in serum samples of different groups of albino rats shown in table 1 and 2, in the group II CCl_4 treated animals showed the level of marker enzymes were significantly evaluated when compared to the normal group I animals, but there was significant increase of the enzyme level ($p < 0.01$) in the *Calotropis procera* extract treated animals group IV and V. CCl_4 treatment resulted in the significant ($p < 0.05$) increase of liver weight compared to vehicle treatment. In *Calotropis procera* treated group, the increase in liver weight was less compared to CCl_4 treated group, while in silymarin treated group, CCl_4 administration did not increase liver weight.

Histopathological examination of liver sections of control group showed normal hepatic cellular architecture. Disarrangement of normal hepatic cells with intense centriobular necrosis, degeneration and

patchy necrosis of hepatocytes are observed in CCl₄ intoxicated liver. Silymarin treated rat are showing normal architecture with very mild degree of proteinaceous degeneration, there is slight periportal mono nuclear infiltration and no patchy necrosis of hepatocyte seen. The liver sections of the rats treated with ethanolic extract of *Calotropis procera* intoxicated CCl₄ showed liver architecture is maintained with normal central vein, no degenerative and necrotic changes seen and overall no visible changes observed, supplementing the protective effect of the extract.

Histological observations basically supported the results obtained from serum enzyme assays. The CCl₄ induced histopathological changes in liver were confirmed in hepatotoxicity. Silymarin and *Calotropis procera* extract reversed the liver to normalcy.

CONCLUSION

The efficacy of any hepatoprotective drug is essentially dependent on its capability of either reducing the harmful effects or in maintaining the normal hepatic physiological mechanism, which have been imbalanced by a hepatotoxin. Orally administered doses of 250 and 500 mg/kg of ethanolic extract of stem of *Calotropis procera* produced significant decrease in SGOT, SGPT, ACP, SALKP and

total bilirubin levels and liver weight. The activity of the extract is found to be dose dependent. In CCl₄ induced toxic hepatitis, toxicity begins with the change in the endoplasmic reticulum, which results in the loss of metabolic enzyme located in the intracellular structures. Administration of ethanolic extracts of *Calotropis procera* showed recovery against the toxic effects of CCl₄. The hepatoprotective effect of the drug was further supported by the histopathological examinations of the liver sections which reveal that the normal liver shape was distributed by hepatotoxin intoxication. In the liver sections of the rats treated with *Calotropis procera* extract and intoxicated with CCl₄ the normal cellular shape was retained as compared to silymarin, thereby confirming the protective effect of the extracts of *Calotropis procera*.

The hepatoprotective activity of *Calotropis procera* could be due to the presence of bioflavonoids which have hepatoprotective properties. The result of this investigation indicated that the ethanolic extract of stem *Calotropis procera* possess hepatoprotective activity against CCl₄ induced liver damage in rats. Attempts are being made to isolate and characterize the active principle to which the hepatoprotective activity can attribute.

Table 1: Effect of 70% ethanolic extract of stem of *Calotropis procera* on biochemical parameters in CCl₄ induced hepatic injury on study day 3

TREATMENT	SGOT Level (IU/L)	SGPT Level (IU/L)	ACP Level (IU/L)	ALP Level (IU/L)	TBL Level (mg/dl)
Control	47±5.962	37.06±2.78	2.5±0.35	47±4.22	0.73±0.07
CCl ₄	218.5±214.52	197.36±14.26	3.34±0.32	323.94±48.1	1.682±0.31
Silymarin + CCl ₄	178.98±9.02	145.54±6.78	3.32±0.27	182.8±24.59	0.872±0.11
250 mg/kg extract + CCl ₄	290.32±74.76	245.48±95.72	2.64±0.22	206.4±11.93	0.96±0.06
500 mg/kg extract + CCl ₄	211.98±22.10	150.98±18.03	2.56±0.17	192.2±7.53	0.944±0.12

Values are expressed as mean ± S.E.M. (n=5) for the groups of 5 animals in each group.

Table 2: Effect of 70% ethanolic extract of stem of *Calotropis procera* on biochemical parameters in CCl₄ induced hepatic injury on study day 7

TREATMENT	SGOT Level (IU/L)	SGPT Level (IU/L)	ACP Level (IU/L)	ALP Level (IU/L)	TBL Level (mg/dl)	Liver weight (gm/kg)
Control	41.08±4.98	35.64±1.30	1.84±0.23	42.64±3.09	0.674±0.08	9.52±0.366
CCl ₄	280.58±29.83	225.52±17.83	3.22±0.60	605.82±31.38	1.238±0.20	11.78±0.573
Silymarin + CCl ₄	178.98±30.08	130.98±6.59	2.8±0.32	213.74±23.66	0.952±0.07	9.76±0.480
250 mg/kg extract + CCl ₄	173.28±8.02	103±2.41	1.52±0.12	216±23.78	0.792±0.04	10.02±0.457
500 mg/kg extract + CCl ₄	151.2±17.69	115.96±16.37	2.06±0.33	205±15.094	0.698±0.08	9.92±0.185

Values are expressed as mean ± S.E.M. (n=5) for the groups of 5 animals in each group.

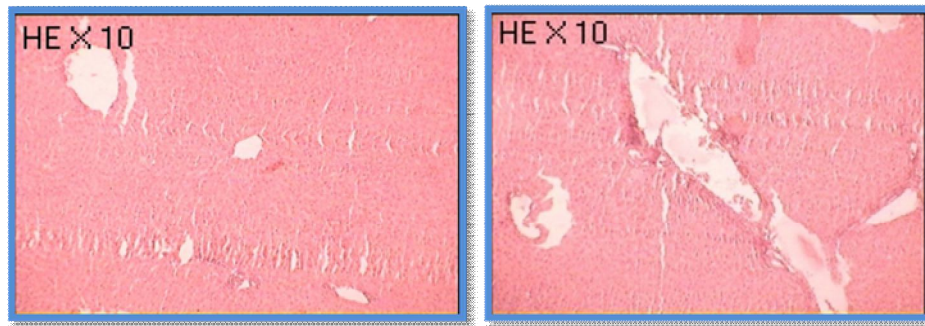


Fig. 1: Normal control rat: section of liver showing normal hepatic cells

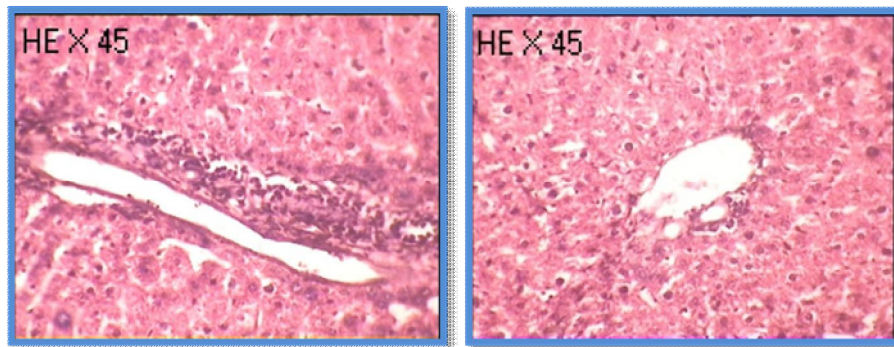


Fig. 2: CCl₄ treated rat: section of liver showing mild fatty degeneration, patchy necrosis of hepatocytes

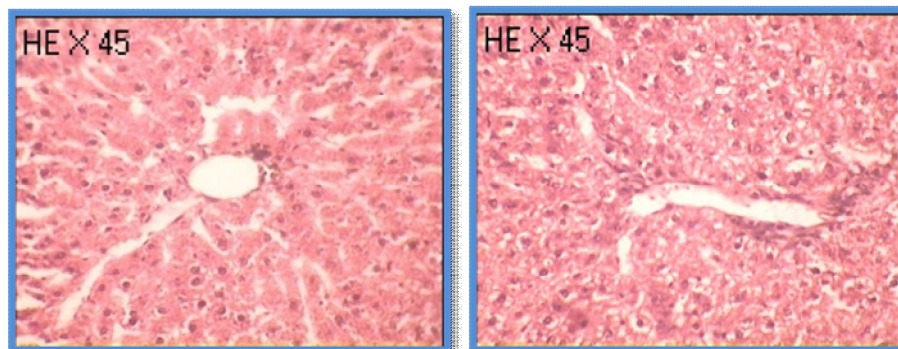


Fig. 3: silymarin treated rats: section of liver showing normal architecture with very mild degree of proteinaceous degeneration, there is slight periportal mononuclear infiltration. No patchy necrosis of hepatocyte

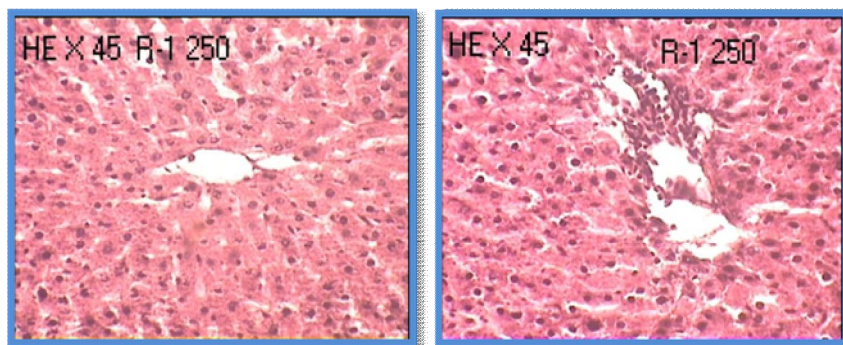


Figure 4: *Calotropis procera* treated rats (250mg/kg): Liver architecture is maintained with normal central vein, no degenerative and necrotic changes seen. There is mild periportal inflammation

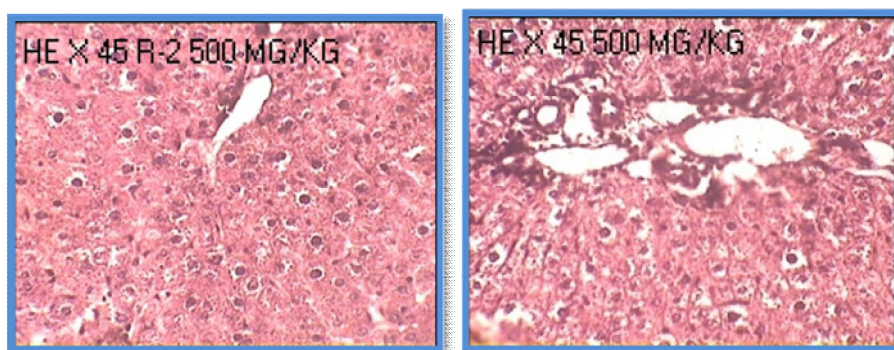


Figure 5: *Calotropis procera* treated rats (500 mg/kg): Liver architecture is maintained with normal central vein, no degenerative and necrotic changes seen. There is mild periportal inflammation

REFERENCES

1. Reddy PB, Reddy CK, Rambhau D, Venkateshvaralu V and Murthy. Anti hepatotoxic activity of some Ayurvedic preparation. Ind J Pharm Sci. 1993;55(4):137-140.
2. Kumar ashwani, Pharmacognosy of *Calotropis procera*, November 5th 2009.
3. Kumar VL, Sangraula H, Dewan S, Kumar Suresh. Anti-diarrheal activity of the latex of *Calotropis procera*. Journal of Ethnopharmacology. 2001;76:115-18.
4. Mossa JS, Tariq M, Mohsin A, Ageel AM, Yahya A, Said A. et al. Pharmacological studies on aerial part of *Calotropis procera*. American Journal of Chinese Medicine. 1991;14:223-231.
5. Sharma P, Sharma JD. In-vitro shizonticidal screening of *Calotropis procera*. Journal of ethnopharmacology. 1999;68(1-3):83-95.
6. Kumar dubey V, jagannadham MV. Procerin, a stable cyseine protease from the latex of *calotropis procera*. Phytochemistry. 2003;62:1057-71.
7. Setty Ramachandra S, Quereshi Ahmed Absar, Swamy Viswanath AHM, Patil Tushar, Prakash T, Prabhu K, Gouda Veeran. Hepatoprotective activity of *Calotropis procera* flowers against paracetamol-induced hepatic injury in rats. Fitoterapia. 2007;78:451-4.
8. Farnsworth, NR. Biological and Phytochemical Screening of Plants. J Pharm sci. 1966;55(3):225.